

Successful Management of Urethral Calculus in a Mare by Manual Lithotripsy

Gyan Singh*, Ravi Dutt¹, Neeraj Arora², Shivanagouda S Patil¹ and Anand Kumar Pandey

Veterinary Clinical Complex, College of Veterinary Science

¹Department of Veterinary Gynaecology and Obstetrics

²Department of Veterinary Surgery and Radiology

Lala Lajpat Rai University of Veterinary and Animal Sciences, Hisar (Haryana) India 125004

*Corresponding Author E-mail: vetgyansaini@gmail.com

Received: 30.04.2018 | Revised: 27.05.2018 | Accepted: 8.06.2018

ABSTRACT

Current case report describes successful treatment of a mare with the signs of straining, dysuria, tenesmus, haematuria and pyuria since 3 months. The animal was pregnant of about 4 months. Clinical examinations revealed the presence of urethral calculus, which was successfully removed by manual Lithotripsy with artery forceps. With proper post-operative care and management, the animal recovered uneventfully without any complications.

Key words: Equine, Haematuria, Lithotripsy, Urethra, Urinary calculus.

INTRODUCTION

The presence of macroscopic concretions of urine crystals within the urinary tract is termed *urolithiasis*. Cases with clinical signs of urinary calculi, uroliths are most commonly encountered in the urinary bladder followed by urethra⁸. In horses, the main crystalloid component of uroliths is calcium carbonate¹ in the form of calcite, the most stable hexagonal crystal form. Haematuria and pyuria can be found in animals with cystic or urethral calculi^{8,5}. The general palpation techniques, ultrasonography, radiographs, endoscopy and some biochemical tests of serum or urine may be helpful in diagnosing the condition⁸. The signs may vary among the cases depending

upon the size and position of the calculi and also duration of the illness². In males, predisposition is more as the urethra is long and narrow compared to the female⁹.

CASE HISTORY AND CLINICAL OBSERVATIONS

A mare of 2.5-years-old presented to the Veterinary Clinical Complex LUVAS-Hisar with the history of dysuria since 3 months, blood mixed urine with pyuria, and tenesmus. According to the owner, the mare was mated 4 months ago. The animal was having normal body temperature (101°F), heart rate of 45 per min and respiratory rate of 18 per min, but there were variations in blood parameters and in routine urine analysis results.

Cite this article: Singh, G., Dutt, R., Arora, N., Patil, S. S. and Pandey, A. K., Successful Management of Urethral Calculus in a Mare by Manual Lithotripsy, *Int. J. Pure App. Biosci.* 6(4): 725-727 (2018). doi: <http://dx.doi.org/10.18782/2320-7051.6452>

Mucus membrane of conjunctiva was pale. Haemoglobin, lymphocyte, neutrophil and total leukocyte count were 6.8 g%, 10%, 90%, and 16.74 thousand, respectively. In routine urine examinations intact erythrocytes were observed under microscope. Trans-rectal real time B mode ultrasonography revealed hyper-echoic mass in the urethra and pregnancy of about 4 months. Per-rectal examination revealed hard structure in the urethra. Using liquid paraffin and lignocaine jelly, digital exploration of urethra revealed presence of hard calculus mass at a distance of 3 inches from external orifice of urethra.

The mare was placed in a stock for examination. The sacro-coccygeal region was prepared for aseptic epidural anaesthesia. The site for needle insertion was identified by moving the tail up and down and palpation of the first articulation caudal to the sacrum. An 18 gauge, 1.5-inch-long needle was inserted in the centre of the palpated depression at a 90° angle to the skin plane. The correct placement of the needle in the epidural space was confirmed using the hanging-drop method and

sensing a lack of resistance in the syringe plunger during solution infusion. In the hanging drop technique where, after the needle is through the skin and subcutaneous tissue, a drop of saline can be placed in the hub of the needle. When the needle enters the epidural space, negative pressure will cause the drop to be aspirated. Four ml of 2% lignocaine Hcl was administered at the above specified place. The effect of epidural anaesthesia was assured by flaccidity of tail. Due to large size of the calculus it was difficult to retract it through the urethra. After epidural anaesthesia with the help of index finger and middle finger the calculus was grasped and then it was broken into 3 pieces by crushing with sterile stainless steel artery forceps and removed with least possible injuries to the urethra and surrounding tissues. Then, the urethra was flushed with 200ml Metrogyl (Metronidazole, J.B. Chemicals & Pharmaceutical Ltd) thrice using sterile IV set and finally douched in 100 ml Metrogyl added with 10 ml povidone iodine solution.



Fig. 1: Urethral calculus recovered from Mare by Manual Lithotripsy

TREATMENT

Following douching the urethra, animal was advised for Inj. Ceftiofur sodium (Xyrofur, Intas pharmaceuticals Ltd, 1g, IM), Inj. Normal saline (2 liters, IV), Inj. Flunixin Meglumine (Megludyne, Virbac India, 15ml, IM), Inj. Mecobalamin (Mecovet-XL, Carus Laboratories Pvt Ltd. 10 ml, IM), Inj.

Metrogyl (Metronidazole, J.B. Chemicals & Pharmaceutical Ltd, 300 ml, IV) for 5 days. In addition to this Inj Clotex (Pail Pharma Pvt. Ltd, 10 ml, IM) for 2 days and Tab. Cystone (Himalaya drug company, 7, PO) for 7 days were also advised. The owner was advised to feed the laxative feed for 5 days. The animal recovered uneventfully.

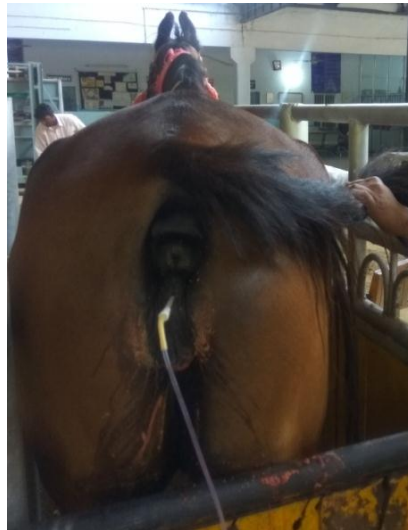


Fig. 2: Flushing of urinary tract after removal of calculus

DISCUSSION

As per telephonic conversation with the owner, the animal recovered without any complication and the micturition was normal. Prognosis is often poor in the bladder paralysis or renal failure cases which may occur in cystic calculi^{6,10} and it also depends on the location of the calculus and duration of hindrance in micturition process. In the present case there was incomplete urinary hindrance and urethral calculus was removed by manual lithotripsy without any surgical intervention. Removal of calculi from the mares is usually accomplished through the distensible urethra³. Fragmentation of the urinary calculi allows the removal of the fragments through a smaller incision, usually through the urethra in mares. Urethral sphincterotomy and manual extraction in females are still the preferred treatments for successful resolving urolithiasis in mares⁴. From the present case report, it is concluded that the cases of urethral calculus/calculi in mare can be managed successfully by manual lithotripsy if located in the urethra within digital approach, thus avoiding the need of surgical intervention.

Acknowledgements

The authors are thankful to Head, Department of Veterinary Clinical Complex, LUVAS Hisar, Haryana (India) for providing necessary facilities for this study.

Conflict of interest none to declare

REFERENCES

1. Diaz-Espineira, M., Escolar, E. and Bellanato, J., Structure and composition of equine uroliths. *J. Equine Vet. Sci.*, **15(1)**: 27-34 (1995).
2. Edwards, B. and Archer, D., Diagnosis and treatment of urolithiasis in horses. *In Practice*, **33(1)**: 2-10 (2011).
3. Firth, E. C., Urethral sphincterotomy for delivery of vesicular calculus in the mare: a case report. *Equine Vet. J.*, **8(3)**: 99-100 (1976).
4. Foley, A., Brounts, S. H. and Hawkins, J. F., Urolithiasis. *Compendium Equine*, **4(3)**: 125-133 (2009).
5. Hanson, R. R. and Poland, H. M., Perineal urethrotomy for removal of cystic calculi in a gelding. *J. Am. Vet. Med. Assoc.*, **207(4)**: 418-419 (1995).
6. Holt, P. E. and Pearson, H., Urolithiasis in the horse - a review of 13 cases. *Equine Vet. J.*, **16(1)**: 31-34 (1984).
7. Katja, F. and Zellmer, D., Equine urolithiasis. *Vet. Clin. Equine*, **3**: 613-629 (2007).
8. Laverty, S., Pasoce, J. R. and Ling, G. V., Urolithiasis in 68 horses. *Vet. Surg.*, **21(1)**: 56-62 (1992).
9. Lillich, J. D., Fischer, A. T. and DeBowes, R. M., Bladder. *Equine Surgery*, 877-887 (2006).
10. Trotter, G. W., Bennett, D. G. and Behm, R. J., Urethral calculi in five horses. *Vet. Surg.*, **10(4)**: 159-62 (1981).